



RESENTING CLINICAL SIGNS

History: Had a 10 minute episode of unsteadiness, vocalizing, hypersalivation. Vomited undigested food the following morning. Thickened intestines on palpation. ECG – sinus rhythm.

DATE

9/10/21

ECHOCARDIOGRAPHIC FINDINGS

2D, M-mode, and Doppler study.

PERFORMED BY:

Jenna Walsh

INTERPRETED BY

Keith Blass, DVM,
MS, DACVIM
(Cardiology)

Left atrial size is normal. The mitral valve is normal. Left ventricular wall thickness is normal. Left ventricular internal dimensions are normal. Left ventricular systolic function is hyperdynamic. The aorta and aortic valve are normal. Right atrial and right ventricular dimensions are normal. The tricuspid valve appears normal, though very mild tricuspid regurgitation is present. The pulmonary artery and pulmonic valve are normal. No shunting lesions are visualized. No pericardial effusion or cardiac masses are seen.

PATIENT

Jude Carr

SPECIES

Feline

LA/Ao – 1.28
IVSd – 4.1 mm
LVPWd – 4.2 mm
LVIDd – 10.8 mm
LVIDs – 3.8 mm
FS – 64.8%
RA – 10.7 mm
LVOT – 0.65 m/s
RVOT – 0.55 m/s
TR – 1.00 m/s

ASSESSMENT/RECOMMENDATIONS

BREED

Persian

This examination demonstrates very mild regurgitation of blood across Jude's tricuspid valve. The hemodynamic effects of the regurgitation also appear to be mild, as Jude does not have secondary dilation of either of his right heart chambers. As such, Jude's current risk for the development of clinical signs of right-sided cardiac dysfunction appear to be low.

SEX

MN

No reason for Jude's episode of unsteadiness, vocalizing, and hypersalivation is appreciated in the image set, and the absence of atrial dilation suggests that a thromboembolic episode of cardiogenic origin did not occur.

AGE

6 y

A Holter and/or event monitor can be considered to evaluate for an intermittent arrhythmia as a possible cause of Jude's episode.

No therapy is recommended based on this exam.

A recheck echocardiogram is recommended in ~12 months, sooner if new clinical signs compatible with cardiac dysfunction develop.

WEIGHT

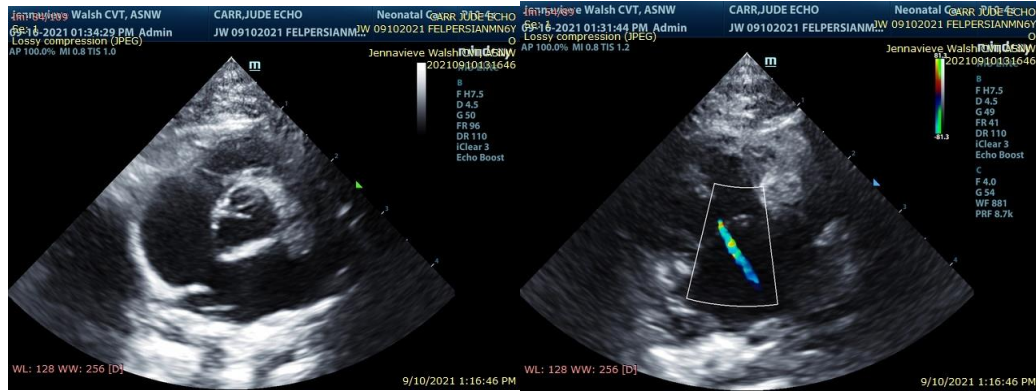
6.9 lb

HOSPITAL NAME

Willakenzie AC

REFERRING VET

Dr. Kairis



DATE

9/10/21

PERFORMED BY:

Jenna Walsh

INTERPRETED BY

Keith Blass, DVM,
MS, DACVIM
(Cardiology)

The information and recommendations provided are based on the images presented by the referring veterinarian. No evaluation can be communicated regarding pathology that was not visible in the image/video clips provided.

PATIENT

Thank you for this referral. If the clinical or image interpretation does not parallel your findings or if I can be of any further assistance please contact me.

Jude Carr

Keith Blass, DVM, MS, DACVIM (Cardiology)
KeithBlass@gmail.com
631-804-5754

SPECIES

Feline

BREED

Persian

SEX

MN

AGE

6 y

WEIGHT

6.9 lb

HOSPITAL NAME

Willakenzie AC

REFERRING VET

Dr. Kairis